

Gynecologist and Breast Cancer

Rao Raja Subbarao¹ Rao Satish Raja²

¹Shushrushta Citizen's Co-operative Hospital, Mumbai. ²Asian Institute of Oncology at SL. Raheja Hospital and Sir Harkisondas Hospital Mumbai.

Key words: breast cancer

Cancers of the breast and uterine cervix are the two most common cancers in women. Breast is regarded as a symbol of femininity; there is a high degree of emotional attachment to this organ. Women are frightened of this cancer. Many feel that the treatment and its sequela are worse than the disease. This results in delay in diagnosis and initiation of treatment. Women often consult their gynecologist for their breast problems. They are more comfortable with their gynecologist, who has treated them earlier for pregnancy or benign gynecological problems, than with an oncologist. The gynecologist has to reassure the woman, if she has benign breast disease, or worried about cancer. On the other hand, if she has a suspicious lesion or frank cancer, the gynecologist should guide her to seek appropriate treatment without any delay.

Tremendous advances have been made in the detection, diagnosis and treatment of this disease. Progress has been made at the molecular level and in genetics of breast cancer. There has been a paradigm shift in our approach to breast cancer. Fifty years ago, the oncologist had only one aim, to save life at any cost. Radical mastectomy

was the gold standard of treatment. It was a sacrilege even to question its rationale. Today, our objective is not only to save life, but also to preserve cosmesis and function. In the case of breast cancer, it means cosmetic considerations and restoration of the body image. The object of this article is to review our status of knowledge and practice of management of breast cancer.

Epidemiology

Breast cancer is the most common cancer in women in the developed countries. It is estimated that nearly a million new cases of breast cancer are diagnosed annually all over the world". Its incidence is increasing, perhaps due to the adoption of Western lifestyle. In USA, 183000 new cases are detected annually- .In India, it is estimated that about 80000 new cases of breast cancer are seen every year- .Fig. 1 shows the incidence of this disease in North America, Europe, Africa, Mumbai, Delhi, Chennai and Barseilly in rural Maharashtra". In Mumbai, Delhi and Kerala, it is the commonest form of cancer in women. In rest of India and particularly in rural areas, cancer cervix is the number one cancer. Breast cancer is a disease of the affluent and has a high

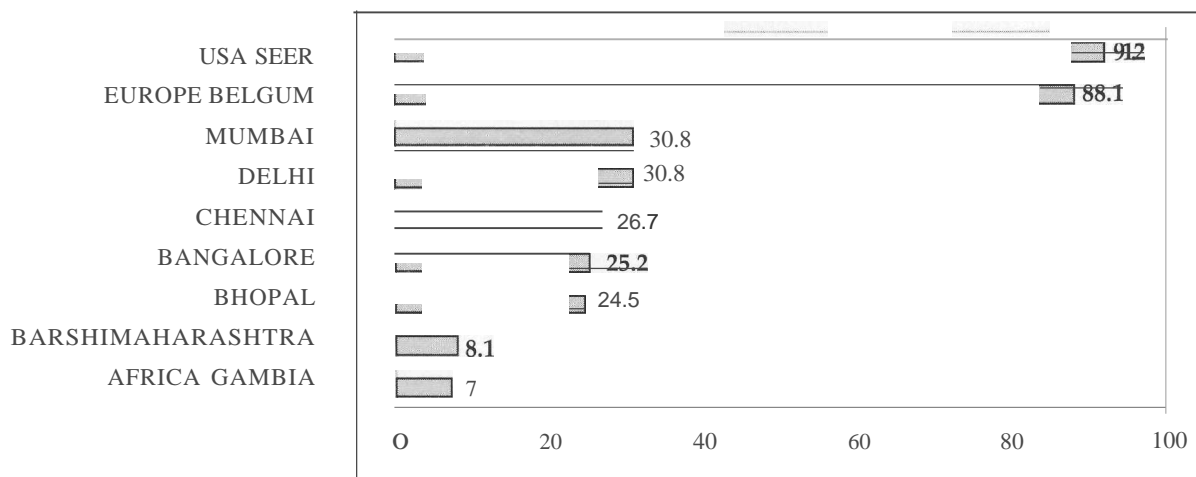


Fig 1 . Age adjusted incidence rates (AAR) of cancer breast in India and other parts of the world. AAR/100000.

Paper received on 24/06/04 ; accepted on 02/08/04

Correspondence :

Dr. R S Rao

Ganesh Niketan, 165/D, Khareghat Road,

Hindu Colony, Dadar, Mumbai - 400 014.

E-mail: drsrao@rediffmail.com

incidence in developed countries, urban areas and in higher strata of society. In contrast, cervical cancer is more prevalent in rural areas and in the low socioeconomic strata of our society. There is also a high incidence in the Parsee community, and in single and nulliparous women".

An important consideration is the age of the woman at the time of her first pregnancy. Women who are thirty at time of first pregnancy have a higher chance of getting breast cancer than women who have their first child at twenty'. In the first pregnancy, the epithelium of the ducts and alveoli of the breast undergoes a process of maturation to prepare them for lactation. These mature cells have a longer cell cycle, allowing them more time in the G1 phase to repair any damage to the DNA and are more resistant to neoplastic change",

The most important single cause of breast cancer is prolonged stimulation of the breast epithelium by endogenous or exogenous estrogen. Women, who have early menarche and late menopause are candidates for this disease? Average age of menarche has come down in developed countries and in higher strata of society. Women, who attain their menopause before the age of 45, have 50% less chance of developing this cancer as compared to women, who attain their menopause after the age of 55⁸. Removal of ovaries in young women also reduces the chances of their getting breast cancer",

There are two important sources of exogenous estrogen viz. oral contraceptives (OC) and hormone replacement therapy (HRT). A meta-analysis of various trials on the role of OC in the etiology of breast cancer has shown that women, who are on these pills and for ten years after the cessation of OC, have a slightly higher risk than the controls (relative risk 1.15-1.33). There is no significant risk in women who have stopped OC for more than ten years", In contrast, hormone replacement therapy (HRT) is associated with increased risk of cancer". The relative risk is 1.35 time higher than in women who are not on HRT. The risk increases with the number of years of exposure to HRT. Once HRT is stopped, the risk decreases. A combination of estrogen and progesterone also increases the risk of breast cancer". Search is on for a drug which protects the women from adverse effects of menopause, without increasing the risk of breast cancer. Raloxifene is one such drug, but it is associated with thrombo-embolic episodes". At the same time, the benefits of HRT should not be denied out of fear of breast cancer. Each case should be carefully individualized and assessed. A careful history of breast cancer in the family is sought. Clinical examination of the breasts and a base-line mammogram is mandatory. The woman should be carefully monitored". A physical examination and mammogram should be done once a year. Women who have suffered from breast cancer should not be put on HRT. In a Scandinavian trial, women who had suffered from breast cancer, were randomized to receive HRT or non-hormonal therapy. The trial was abandoned midway as the incidence of relapse or new primary breast cancer was higher in women receiving HRT¹³. The

relation of lactation with breast cancer is not clear. Studies have suggested that a long duration of lactation reduces the risk of breast cancer in pre-menopausal women".

Other risk factors

There is a definite relationship between middle aged obesity and breast cancer. Several studies have been undertaken to establish a relationship between dietary fat intake, its saturated and unsaturated fractions and breast cancer. There is no convincing evidence of any relation between breast cancer and dietary fat intake". The risk of breast cancer increases with increased consumption of alcohol". There is no evidence to show any relation between breast cancer and intake of fibres, vitamins and minerals.

Benign breast disease and cancer

Benign breast disease is classified as proliferative and nonproliferative. The proliferative type is associated with high risk of breast cancer, ego duct papilloma, atypical hyperplasia¹⁸. Women with nonproliferative lesions like fibroadenomas or cysts are not at increased risk for developing cancer. These lesions constitute 70% of surgery for benign breast disease.

Family history

It is not uncommon to find that breast cancer runs in families. We often come across cases of breast cancer in sisters, mother and daughter, aunt and niece and so on. Such occurrences are not necessarily hereditary, but may be because of similar endocrine profile and lifestyle.

Genes and breast cancer

There are two suppressor genes, which are associated with high risk of breast and ovarian cancer, viz. BRCA 1 and BRCA 2. They are transmitted to the offspring either through maternal or paternal lineage". It is possible to detect mutation in these genes. Only 7% of women, from families with history of breast cancer, tested positive for mutations of BRCA1/2. Mutation of P 53 gene is also seen in some cases of breast cancer. Another abnormality is the over expression of c-ERB 2 gene or HER-2/neu. Those, who test positive for over expression of this gene, have a more aggressive course of disease and respond only to anthracycline (Adriamycin). An antibody called herceptin has been developed against this gene and has been used on patients. However, this drug has significant cardiac toxicity.

Prevention of breast cancer

The most important cause of breast cancer is endogenous estrogen. We can do little to prevent this cancer. A number of prospective trials have been conducted, using

tamoxifen in high risk women with appropriate controls. The NSABP trial (American trial) showed that tamoxifen was successful in preventing breast cancer". The British and European trials, however, did not show any protective effect of tamoxifen in prevention of this disease^{22,23}. Physical examination of the breast, either by gynecologist / surgeon or by the woman herself, helps the detection of cancer at an earlier stage.

Physical examination of the breast

The most important clinical sign to be sought is the presence of a lump in the breast. Examination of the breasts should be done with the woman stripped upto the waist. Examination of the breast with the woman partially undressed can lead to wrong conclusions. A lump in the breast or an axillary lymph node can be missed. The breasts should be inspected with the woman sitting and then in lying down position. The position of the nipple, its retraction if any, discharge, edema of the areolar skin, peau-d-orange, dimple or tethering of the skin are noted. The breast is divided into five regions viz. upper and outer quadrant, upper and inner quadrant, lower and outer quadrant, lower and inner quadrant and the retro-areolar region. The breast should be palpated with the flat of the hand. The fingers are kept close together and extended. Palpation is done with the palmer surface of the middle phalanx. All the quadrants are systematically palpated, from the periphery towards the centre. If the breast is palpated between the thumb and the fingers, nodularity will be felt even in the normal breast. The axilla and supraclavicular fossa are palpated next. Similar procedure is repeated on the opposite breast.

Discharge from the nipple is a common symptom. The discharge may be watery, serous, greenish, milky or bloody. Only blood stained discharge needs surgical treatment. Blood stained discharge is due to duct papilloma or duct carcinoma. The affected duct is identified, excised and sent for histological examination. If the report is a papilloma, no further treatment is indicated. If the report shows a carcinoma, further treatment is carried out as indicated. Recently, ductal endoscopy has been introduced. This procedure permits visualization of the ducts and collection of washings for cytological examination. The utility of ductal endoscopy still needs to be evaluated.

Women can be taught to examine their own breasts, i.e., breast self examination (BSE). This should be done immediately after the menstrual period, when there is no congestion of the breast. BSE should be started early, in the third decade and become a part of routine body care. If BSE is started at a later age, say around 40 years, an element of fear creeps in. In some women, the fear is

excessive and can lead to neurosis. The objective of BSE is to encourage women to seek medical help at an earlier stage of the disease. After an initial period of enthusiasm, many women give up BSE. An annual medical check up of women for major diseases like cancer, hypertension, diabetes is more rewarding. Cancer check up must include physical examination of the breasts, pelvic organs, mammography, Pap smear and pelvic sonography.

Imaging of the breast

In mammography, x-ray of the breast is taken in two views, cranio-caudal view and medio-lateral view. It is then possible to localize the lesion. Mammogram demonstrates areas of abnormal density (Fig.2) The most important sign is presence of micro-calcification, pin head size and spiculation. Dense amorphous calcification is seen in benign disease. Most radiologists report their findings as per "Breast Imaging Reporting and Data System" (BIRADS), a universally accepted system of classifying mammographic appearance". This system is graded as I to V. BIRADS I is normal and benign and BIRADS V is frankly malignant. Sorio-mammography is complementary to mammograms. It is particularly useful to detect cysts, duct ectasia and duct papilloma.

Mammograms are very useful in detecting small lumps in large breasts, where clinical palpation is likely to miss small lumps. It is very useful as a screening procedure in menopausal women. It is of limited value in younger

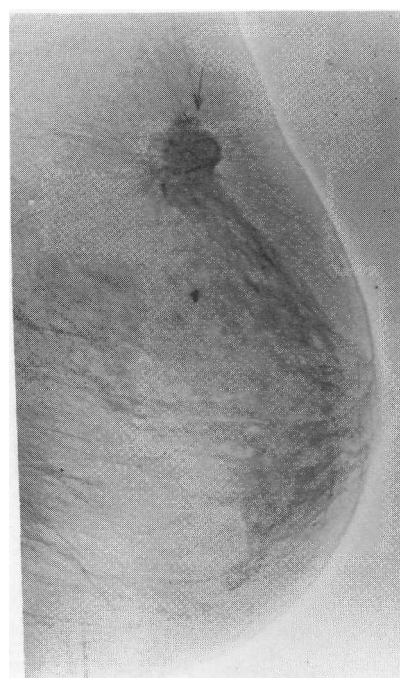

Fig 2 . Breast Cancer

women, in whom there is a higher proportion of glandular tissue. In young women, mammography picks up many benign lesions, which lead to needless biopsies and excisional surgery. Mammography is not useful in small breasts, where clinical examination is unlikely to miss the lump. Nonpalpable, mammographically detected cancers are called screen detected breast cancers

Microscopic diagnosis of breast cancer

It is absolutely essential to obtain microscopic proof of diagnosis before embarking on treatment. The following options are available to obtain microscopic proof.

1. *Fine needle aspiration cytology (FNAC)*. It is a very popular method of obtaining diagnosis. Since the advent of FNAC, the incidence of frozen section has come down drastically. About 80% of cases can be diagnosed by FNAC. FNAC should be performed by a competent surgeon or pathologist, who is familiar with the technique, scope and limitation of the procedure. A fine needle, 23/24 gauge, is used with a 5mL syringe. The lump is localised and immobilized between the thumb and the fingers or by an assistant. The needle is thrust into the mass and negative suction is applied, when the needle is being moved in the lump. The negative pressure is maintained, till the needle is disconnected from the syringe. During the whole procedure, care is taken not to allow the aspirate to enter the syringe. The contents of the needle are pushed on a slide, smears are prepared and a fixative is sprayed on the smear. The cytopathologist stains the smears and examines them under the microscope. The sensitivity of this procedure is 96%, specificity 99% and false positive rate is less than 0.5%²⁵. Negative FNAC report does not exclude cancer. There may be sampling errors. The lump may have slipped out of the range of the needle. Smears may have dried up, material may be scanty, or the microscopic appearance may be equivocal. If the FNAC report is negative and a lump is palpable, it demands excision and histological examination. FNAC is a diagnostic tool and not a modality of treatment. Negative FNAC does not mean that the lump can be observed.

2. *True cut biopsy*. In this method, a core of tissue is obtained and sent to the laboratory. The diagnosis is made on histopathology and not on cytology. Hormone receptor studies can be done on the paraffin blocks prepared from this tissue.

3. *Frozen section*. The whole or part of the lump is excised and submitted for frozen section. If the report is positive, further definitive procedure is carried out at the same sitting. Occasionally, the pathologist is unable to give a diagnosis on frozen section. In that case, we have to wait for the opinion on paraffin sections.

Metastatic workup. Before embarking on the treatment, the patient should have a chest x-ray, ultrasound of the abdomen and pelvis, and isotope bone scan. Routine hematological and biochemical investigations are done. When indicated, CT scan of the chest, abdomen or brain is done. If needed, MRI of the spine or other bones is done to confirm isotope bone scan findings. In cases suspected to have extensive skeletal metastases, a bone marrow biopsy may be done. A baseline mammogram is done to exclude multicentric lesion in the ipsilateral breast and occult primary in the opposite breast. Ca 15.3 is a tumor marker for breast cancer. It has a low sensitivity for diagnosis. Its utility does not achieve the level of Cam in ovarian cancer or PSA in prostatic cancer.

Duct carcinoma in situ (DCIS)

In this lesion, the malignant cells are confined to the ducts or alveoli of the breast and have not invaded the stroma surrounding the ducts. These lesions are also called as intraduct carcinoma. With the advent of mammography, there has been a sharp increase in the incidence of DCIS. In USA about 40000 cases of DCIS are detected every year.¹¹ There are several controversies about its management. No one can predict as to how long it will take for DCIS to become invasive cancer. DCIS can be multicentric in the same breast. DCIS is graded as well differentiated, intermediate and high grade. The morphological appearance is described as comedo, cribiform, papillary, etc. Presence of necrosis is documented. These factors are important for deciding the modality of treatment. Comedo type and necrosis indicate a more aggressive behavior. If DCIS is multicentric or spread over a large area, a mastectomy is indicated.

Management of DCIS and screen detected cancer. Majority of DCIS are detected on mammography and clinically not palpable. The lesion is localized by placing a thin hooked wire under mammographic control. The hook prevents the wire from slipping out. At times, the localization can also be done by ultrasound. The lesion is then excised with adequate margins. X-ray of the specimen is taken to ensure that the correct area has been removed completely. (Fig. 3) The specimen is then sent for frozen section. If the excised tissue is very small, the pathologist may ask the surgeon to wait for report on paraffin sections. The pathologist opines whether the lesion is only a DCIS or there is an invasive component. Microinvasion means the invasion is less than 1 mm. He also comments on the size and extent of DCIS, its morphological type and grade. Most importantly, he tells us whether the cut margins are free of disease.

The choice of treatment is a mastectomy or lumpectomy followed by radiotherapy. If the DCIS is extensive or multicentric, then a mastectomy is indicated. It is

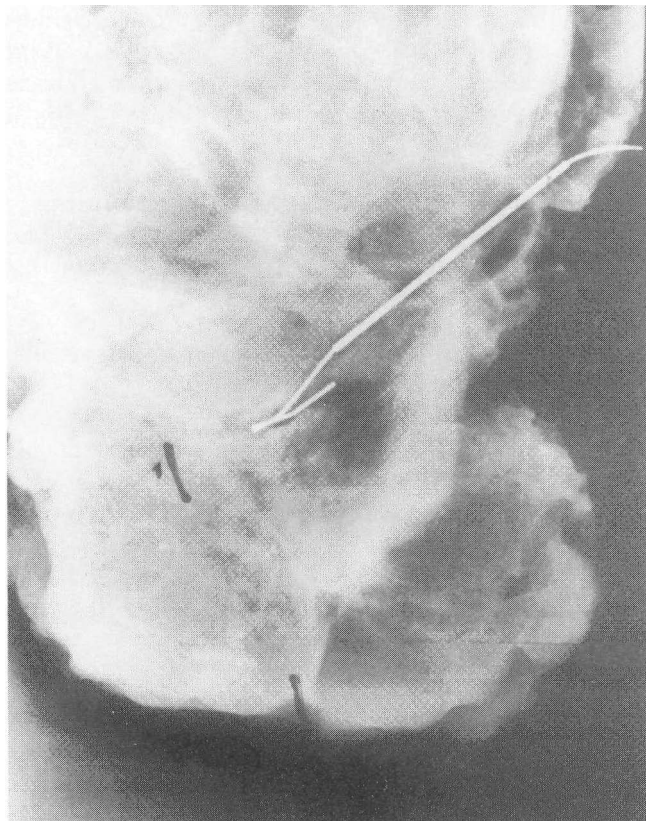


Fig 3 . Breast cancer on x-ray

preferable to do a mastectomy if there is blood stained discharge from multiple ducts. In other cases a lumpectomy is advocated. If one is satisfied that there is no invasive element, axillary dissection is not indicated." Lumpectomy is followed by radiotherapy to the breast. Results of prospective clinical trials have shown that the results of lumpectomy followed by radiotherapy are superior to lumpectomy alone." If the tumor is ER+ve then the patient is put on tamoxifen 20 mg per day for five years.

Histological variants of cancer breast

Lobular carcinoma in situ (LCIS) The other in situ lesion is lobular carcinoma in situ. The lesion arises from the epithelium lining the lobules or alveoli and not from the ducts. It is multicentric and frequently bilateral. LCIS can progress to invasive lobular carcinoma. There is also a high incidence of invasive duct carcinoma in women with LCIS. In view of multicentricity, bilateral lesions, and high risk of invasive duct carcinoma, the ideal treatment is bilateral mastectomy".The other alternative is close follow up for life.

The most common histological type of cancer is infiltrating duct carcinoma. The other variants are papillary carcinoma and medullary carcinoma,colloid

carcinoma, inflammatory carcinoma. Grading of the tumor is important. Estrogen and progesterone receptor studies and over expression of the HER-2/ neu gene are carried out on the paraffin sections.

Staging of breast cancer

Table 1 shows the current AJCC-TNM staging of breast cancer".T1 /T2, with NO/N1 are considered as early or 'operable' breast cancer. 'Operable' means that these lesions are potentially curable by a radical mastectomy. Cases, in whom the primary is more than 5 cms and /or have large fixed axillary nodes (T3/4 or any T with N2), are considered as locally advanced breast cancer (LABC)

Treatment of early breast cancer

Today, there are two accepted methods of treatment viz. modified radical mastectomy (MRM)and breast conservation surgery(BCS) with radiotherapy. In MRM, the whole breast with axillary lymph nodes is removed en bloc. The pectoralis major muscle is preserved; hence the procedure is called modified radical mastectomy. Preservation of the pectoral muscle reduces the morbidity of the classical radical mastectomy. Movements of the shoulder are better. It is easier to fit in a prosthesis.

The other alternative is BSC. In this procedure, the lump is widely excised through a curvilinear incision, placed over the lump. Care is taken to see that the cut margins are free of disease. Through a separate incision in the axilla, an axillary lymph node dissection is performed. Surgery is followed by radiotherapy to the whole breast . A dose of 5000 cg is delivered to the whole breast. An additional booster dose is given to the site of the primary. The axilla is not irradiated. Postoperative chemotherapy is given when indicated . There is enough data available to show that the results of BCS are as good as that of MRM^{30,31} .There is additional benefit that the breast is preserved .Excellent cosmetic results have been achieved. (Fig.4) However not all cases of early breast carcinoma are suitable for BCS. An important consideration is that the end result is cosmetically acceptable. If lumpectomy results in a mutilated breast, it is better to do a mastectomy and fit a prosthesis. Each case has to be individualized and then chosen for conservation surgery. The following are some of the contra-indications:

1. Lump more than 4 cms in diameter. Smaller the lump, better the cosmetic result.
2. A small breast or large pendulous breast.
3. Multicentric disease as seen on the mammogram .
4. Old age, poor cardio-respiratory status which precludes radiotherapy.
5. Lack of facilities for radiotherapy. This is an important consideration in our country. If a woman

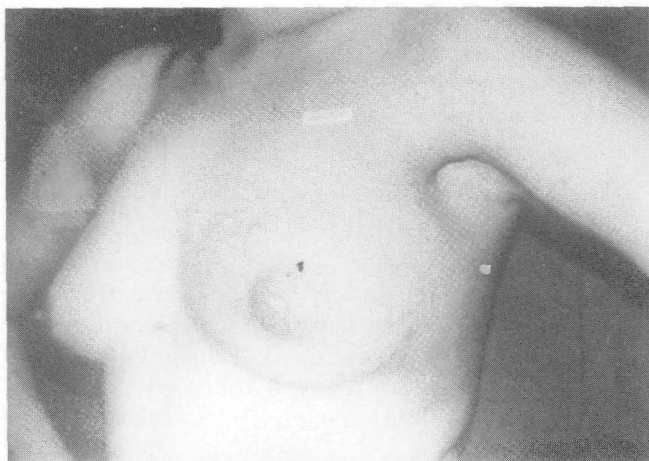

Fig 4 . Breast Cancer

fails to complete radiotherapy because of socio-economic reasons, the choice of treatment was wrong for her. She would have been better off with a MRM.

Extent of axillary dissection and the sentinel node

Axillary nodes are divided into three levels. Level I are nodes lateral to the insertion of pectoralis minor. Level II are nodes behind pectoralis minor. Level III are nodes medial to the minor muscle. Level III nodes carry poor prognosis. Today, cancers are being diagnosed in very early stages. Many cases are screen detected. In such cases, the incidence of positive nodes is very low. Many question the need to perform a full clearance of axilla in all cases. Axillary dissection has some morbidity. There is mild degree of edema of the arm. In some cases it can be severe. There is loss of sensation in the axilla and inner surface of the upper arm due to section of intercosto-brachial nerve. This has led to the concept of the sentinel node. This is the first node to be involved by disease. It can be identified by injecting a dye / radioactive isotope in the peri-tumoral area. On exposure of the axilla the sentinel node is the one containing the dye, or the isotope. It is excised and sent for frozen section. If the sentinel node is positive, then a complete axillary dissection is done. If it is negative, the wound is closed. The sentinel node has a false negative rate of 1.4%. Further studies need to be carried out before it can be recommended as a standard procedure.

Breast reconstruction

Women who undergo a mastectomy, need to be rehabilitated by one of the following -

1. Excellent external prosthesis is available, tailored to individual needs. With a properly fitted prosthesis, it is difficult to state that any surgery has been done on the breast.

2. The other alternative is to introduce prosthesis under the skin. The first step is to introduce a tissue expander to create a space under the pectoral muscle. At the second stage, a suitable prosthesis is introduced.
3. The breast is reconstructed by rotating a myocutaneous flap into the operated area. Two flaps are commonly used viz. rectus abdominis flap (TRAM) and latissimus dorsi flap.
4. Reconstruction of the breast using micro-vascular techniques.

Reconstructive surgery can be undertaken immediately after the mastectomy, at the same sitting. Alternatively, it can be undertaken as a delayed procedure at a second sitting. The only contraindication for immediate reconstruction is the need for post-operative radiotherapy. These days, this is an uncommon event in early cases.

Adjuvant therapy.

Radiotherapy.

Post operative radiotherapy is mandatory after BCS. Post operative radiotherapy after MRM reduces the incidence of local recurrence; it does not affect the overall survival". It is therefore given only in cases, where the surgeon feels that the chances of recurrence are high, ego residual disease left behind or extensive nodal metastases. The morbidity of radiation is radiation damage to the lungs, heart and edema of the arm.

Chemotherapy

Chemotherapy administered before surgery is termed as neo-adjuvant chemotherapy. Post-operative chemotherapy is termed as adjuvant therapy. Treatment of breast cancer has two aspects viz., loco-regional treatment, like surgery and radiotherapy and systemic therapy. It can be chemotherapy or hormonal therapy. Ultimately patients die, not due to local recurrence, but, due to metastases to lungs, liver, brain or bones. In order to save lives, effective systemic therapy should be given.

A high percentage of patients with early cancer will be cured by MRM alone. The object of adjuvant chemotherapy is to improve the overall survival. Several prospective clinical trials have been conducted-v'. Their results clearly show an improved survival with chemotherapy. The Oxford overview conducted a meta-analysis of 69 clinical trials involving about 30000 women". The study showed an improvement of survival by 5.7% in node negative patients, below the age of fifty. The 10 year survival was 77.6% in chemotherapy arm and 71.9% in the control arm. In node positive patients,

below the age of fifty, the 10 year survival was 53.8% in the chemotherapy arm as compared to 41.4% in the control arm, a benefit of 12.4%. Younger and premenopausal women benefited more with adjuvant chemotherapy than older, post-menopausal women. There are several protocols of adjuvant chemotherapy for breast cancer. The most common ones are :

1. CMF. This consists of three drugs- cyclophosphamide, methotrexate and 5-fluoro-uracil. It has stood the test of time. Usually six cycles are given at interval of 3 weeks.
2. AC. Anthracycline (Adriamycin) and cyclophosphamide (endoxan) are given. Four cycles are given at interval of 3 weeks. It is slightly superior to CMF regime. Adriamycin is cardiotoxic. Evaluation of cardiac status, including a 2D echo, should be done by a cardiologist prior to initiation of the therapy. It is strongly irritant to local tissues. Extravasation can lead to sloughing of the tendons. It is also more expensive. For these reasons CMF regime has greater appeal among general physicians and surgeons in our country.
3. Taxanes. Many oncologists follow up AC regime with four courses of taxanes like paclitaxel. Taxanes are expensive.

Chemotherapy has important side reactions. They are leucopenia, fall in platelet count, lowered immunity and alopecia. Women are particularly upset with loss of hair on the scalp. Many have to use a wig for few weeks. After the cessation of chemotherapy, the lost hair is regained. Many premenopausal women develop amenorrhea for varying periods, from few months to two years or more.

Indications for chemotherapy. We should have a detailed report from the pathologist before deciding on chemotherapy. We should also know about their menstrual status and report on hormone receptor, HER-2/neu studies. Chemotherapy is indicated in patients with T size more than 2cms or positive axillary nodes. Women with HER-2/neu positive should be put on anthracycline based therapy. Postmenopausal women with ER +ve and low axillary burden of metastases are put on tamoxifen alone.

Hormonal therapy

The most widely used drug is tamoxifen. Tamoxifen blocks the estrogen receptor sites, thus preventing the uptake of the hormone by breast cells, both normal and malignant. It has no anti-estrogen effect at other sites like the bone. It acts as estrogen agonist on the endometrium, causing thickness of the endometrium.

Rarely, it leads to endometrial cancer". Therefore, patients on tamoxifen should have an annual gynecological check up and pelvic ultrasound. The endometrial thickness is carefully monitored. If there is bleeding, then a diagnostic curettage should be carried out. Tamoxifen, otherwise, is a safe drug. It is given, 20 mg orally, daily for five years. It is known to improve the overall survival by 17% and reduce the chances of disease in the contralateral breast. by 39%.³⁷ These effects are seen in ER+ve patients. Post-menopausal women respond better than pre-menopausal women to tamoxifen. Those who relapse while on tamoxifen are put on a new group of drugs called aromatase inhibitors. These drugs prevent the synthesis of estrogens by the adrenal gland, which is the source of the hormone in post-menopausal women. The drugs used are letrozole (femora), and anastrozole (arimidex) and exemestane. Aromatase inhibitors are used mainly in metastatic cancer rather than in an adjuvant setting.

Locally advanced breast cancer (LABC)

In India, large number of cases present as locally advanced breast cancer. LABC cases comprise of cases where the tumour size is more than 5 cms or there is wide involvement of skin, peau-d-orange, or involvement of the pectoral muscle. The nodes may be large, matted, with edema of the arm. Supraclavicular nodes may be enlarged. However, there are no distant metastases. The first step is to perform a true cut biopsy to get a histological diagnosis and also the receptor status. A thorough metastatic work up is done to exclude distant metastases.

Treatment

There is a small subgroup of LABC, where a MRM is feasible. These are cases where the tumor is more than 5 cm in a large breast. The lump is mobile and nodal status is NO or N1. In these cases, a modified radical mastectomy is done first, followed by adjuvant chemotherapy and radiotherapy. In other cases, the local disease is too advanced for a MRM. The first step is to give neo-adjuvant chemotherapy. Usually two courses of CMF or AC are given. There is usually more than 50% regression and the lesion becomes operable. If the patient is ER+ve then she is also put on tamoxifen. A modified radical mastectomy is performed. The objective is to debulk the disease. Care is taken to obtain a primary closure of the wound. Surgery is then followed by further courses of chemotherapy. After conclusion of chemotherapy, radiotherapy is given to the chest wall, axilla, supraclavicular fossa and the internal mammary nodes. If she is on tamoxifen, it is continued for five years. Patients who respond to chemotherapy have better survival. LABC, broadly, consists of two groups

1. the disease is slow growing, indolent; patient has neglected resulting in delay in seeking medical help. 2. The disease is biologically aggressive and the disease is of short duration. The former group has a better outlook":

Management of metastatic disease

A woman may have metastatic disease at the time of first presentation or, metastases may be detected during the follow up. Since the disease is systemic, chemotherapy and hormonal therapy play an important role. If the tumor is ER+ve, she should be put on tamoxifen. If she has relapsed, while on tamoxifen, she should be put on aromatase inhibitors like letrozole. If she develops resistance to it, she should be put on progesterone derivatives like medoxy progesterone acetate or megestrol. Usually, soft tissue metastases, pulmonary lesions and skeletal metastases respond well to hormone therapy. Should hormonal therapy be given first in ER+ve patients or combined with chemotherapy? It depends on the extent of metastases. One has to assess the effect of delaying chemotherapy on overall survival. Each case has to be individualised. The quality of life on only hormonal therapy is better. ER -ve patients have to be put on chemotherapy. If she has received CMF earlier, she should be put on adriamycin and taxols. Other chemotherapeutic drugs may also be tried.

Locoregional treatment of metastases. In addition to systemic therapy, some metastases require local treatment. They are as follows:

1. Brain. Irrespective of the size or number of metastases, the whole brain must be irradiated. Chemotherapy is of little value as many of them do not cross blood brain barrier. Patient should be alert enough to cooperate and stay alone in a room during radiotherapy. They are also put on steroids to reduce cerebral edema. In acute cases, mannitol is given.
2. Lungs. If the patient has pleural effusion, it is tapped and intra-pleural cyclophosphamide is given. If the effusion fills up rapidly and there are no other metastases, intercostal drainage followed by instillation of bleomycin is done. Women with pulmonary metastases will get relief from steroids, deriphylline and oxygen.
3. Pericardial effusion requires urgent drainage to prevent cardiac tamponade
4. Skeleton. The most common site affected is the spine. Bone metastases are picked up on isotope bone scan. However, these scans have a high false positive rate and need confirmation with x-rays or MRI.

Radiotherapy is given to those who have pain. If there is evidence of pressure on the cord or impending paraplegia, a decompression laminectomy is done first, followed by radiotherapy. Metastases in weight bearing bone, eg neck of femur, or cases with frank or impending fracture should first undergo operation for internal fixation, to be followed by radiotherapy. Patients with extensive skeletal metastases, can be treated with radioactive phosphorous or strontium. They can also be treated with harni-body radiation. These cases are also treated with biphosphonates to prevent hypercalcaemia. It also reduces the bone pain.

5. Krukenberg tumor. Breast cancer has a predilection for endocrine organs, particularly the ovary. Many of them are incidental findings; occasionally, they may present as palpable ovarian tumor. They need to be removed by a laparotomy. The pathologist should tell us whether it is a metastatic lesion or a primary ovarian tumor. Both can co-exist. Ca₁₂₅ levels are useful in making this distinction.
6. Metastases to the adrenals are common. Metastases have also been reported in the pituitary with development of diabetes insipidus".
7. Patients with metastases in the choroid present as cases of detachment of retina.
8. Liver metastases respond poorly to hormonal or chemotherapy. They are treated symptomatically for relief of pain and jaundice.

Our objective in treating metastatic disease is to palliate, improve quality of life and hopefully prolong the survival.

Cancer breast and pregnancy

Cancer breast associated with pregnancy is a challenge both to the obstetrician and the oncologist. Its incidence is estimated as 1 in 1000 pregnancies." Pregnancy does not affect the clinical and biological course of the disease. When the results of treatment in pregnant women are compared with nonpregnant women, of similar age group and stage of the disease, there is not much difference in survival figure⁴⁰. There is a higher incidence of lymph node metastases in pregnant women. There is usually some delay in detecting cancer in pregnant women. Breast examination is more difficult in pregnant women. Often, the possibility of cancer in a young woman is not entertained by the clinician. Mammography is not helpful due to increased density of breast tissue. The diagnosis is established by FNAC or true cut biopsy. The pathologist should be informed that the patient is pregnant.

Treatment. The treatment is decided jointly by the oncologist and the obstetrician. Psychological counseling is required to the patient and her family to calm and reassure them. This will help the patient to take the right decision. To terminate the pregnancy or not, is an individual decision. For early cases, and in the first two trimesters of pregnancy, MRM is the treatment of choice. Radiotherapy is absolutely contraindicated. If one does breast conservation surgery, there is unacceptable delay in starting radiotherapy. Chemotherapy is absolutely contraindicated in first trimester. It can lead to abortion or birth defects, particularly of the central nervous system. In later trimesters, this risk is not there. Many chemotherapy drugs cross the placental barrier. The fetus can suffer from toxicity of the drugs, like anemia, lowered immunity, low birth weight and possible cardiac damage due to adriamycin. Despite all these problems, many women have delivered normal babies. In the third trimester, one can wait for delivery before starting post-operative chemotherapy or radiotherapy. Breast conservation can be considered as an option in the third trimester. Delivery may be conducted earlier to facilitate adjuvant therapy, if indicated.

Reach to recovery programme

A woman, who has been treated for breast cancer, faces several problems. They range from limitation of arm movement, cosmesis, body image, family and social adjustments, sex, marriage, future pregnancies, depression and so on. She should be encouraged to participate in a support group consisting of a trained nurse, social worker and women who have been treated previously for this disease. Some women may require psychological counseling to help them overcome their problems.

References.

- McPherson K, Steel CM, Dixon JM. ABC of Breast Cancer, Epidemiology, Risk factors, and Genetics. *BMJ* 2000;321 :624-8.
- Greenlee RT, Murray T, Bolden S et al. Cancer Statistics, 2000. *CA Cancer J Clin* 2000;50: 7-33.
- Rao ON, Dinshaw KA. Breast Cancer, Incidence, Risk factors and Survival Rates. *Hospital Cancer Registry, Tata Memorial Hospital Mumbai* 1999:6-7.
- Nandkumar A, Thimma Setty KT. Two-Year Report of the Population Based Cancer Registries Incidence and Distribution of Cancer 1997-98. *Indian Council of Medical Research* 2002:27.
- Trichopoulos O, Hsieh Cc, MacMahon B et al. Age at any birth and breast cancer risk. *Int J Cancer* 1983; 31:701-4.
- Lagiou A, Lagiou P, Vassilarou OS et al. Comparison of age at full term pregnancy between women with breast cancer and women with benign breast disease. *Int J Cancer* 2003; 107: 817-21.
- Kelsey JL, Bernstein L. Epidemiology and prevention of breast cancer. *Am J Rev Public Health* 1996; 17: 47-67.
- Trichopoulos O, MacMahon B, Cole P. Menopause and breast cancer risk. *Int J Cancer* 1972; 48: 607-13.
- Breast cancer and hormonal contraceptives: collaborative reanalysis of individual data on 53297 women with breast cancer and 100239 women without breast cancer from 54 epidemiological studies. Collaborative Group on Hormonal Factors in Breast Cancer. *Lancet* 1996; 347: 1713-27.
- Breast cancer and hormone replacement therapy: collaborative reanalysis of data from 51 epidemiological studies of 52705 women with breast cancer and 108411 women without breast cancer. Collaborative Group on Hormonal Factors in Breast Cancer. *Lancet* 1997; 350: 1047-59.
- Ross RK, Paganini-Hill A, Wan PC et al. Effect of hormonal replacement therapy on breast cancer risk: estrogen versus estrogen plus progestin. *Nat Cancer Inst* 2000; 92: 328-32.
- Cummings SR, Eckert S, Krueger KA et al. The effect of raloxifene on risk of breast cancer in postmenopausal women: results from the MORE randomized trial. Multiple Outcomes of Raloxifene Evaluation. *JAMA* 1999; 281:2189-97.
- HABITS (Hormonal Replacement Therapy After Breast Cancer. Is It Safe?): A Randomized Comparison Trial Stopped. *Obstet Gynecol Surv* 2004; 59: 442-3.
- Newcomb PA, Storer BE, Longnecker MP et al. Lactation and a reduced risk of premenopausal breast cancer. *N Engl J Med* 1994; 330: 81-7.
- Huang Z, Hankinson SE, Colditz GA et al. Dual effects of weight and weight gain on breast cancer risk. *JAMA* 1997; 278: 1407-11.
- Holmes MD, Hunter OJ, Colditz GA et al. Association of dietary fat and fatty acids with risk of breast cancer. *JAMA* 1999; 281: 914-20.
- Gapstur SM, Potter JD, Sellors TA et al. Increased risk of breast cancer with alcohol consumption in postmenopausal women. *Am J Epidemiol* 1992; 136: 1221-31.
- Dupont WD, Page DL. Risk factors for breast cancer in women with proliferative breast disease. *N Engl*

J Med 1985; 312: 146-51.

19. Berry DA, Parmigiani G, Sanchez] et al. Probability of carrying a mutation of breast-ovarian cancer gene BRCA1 based on family history. *J Natl Cancer Inst* 1997; 89: 227-38.
20. Couch FJ, De Shano ML, Blackwood MA et al. BRCA1 mutations in women attending clinics that evaluate the risk of breast cancer. *N Engl J Med* 1997; 336: 1409-15.
21. Fisher B, Costantino JP, Wickerham DL et al. Tamoxifen for prevention of breast cancer: report of the National Surgical Adjuvant Breast and Bowel Project P-1 Study. *J Natl Cancer Inst* 1998; 90: 1371-88.
22. Powles T, Eeles R, Ashley S et al. Interim analysis of the incidence of breast cancer in the Royal Marsden Hospital tamoxifen randomized chemoprevention trial. *Lancet* 1998; 352: 98-101.
23. Veronesi V, Maisonneuve P, Costa A et al. Prevention of breast cancer with tamoxifen: preliminary findings from the Italian randomized trial among hysterectomised women. Italian Tamoxifen Prevention Study. *Lancet* 1998; 352: 93-7.
24. Laquement MA, Mitchell O, Hollingsworth AB. Positive predictive value of the Breast Imaging Reporting and Data System. *J Am Coll Surg* 1999; 189: 34-40.
25. Sneige N. Fine-needle aspiration of the breast: a review of 1995 cases with emphasis on diagnostic pitfalls. *Diagn Cytopathol* 1993; 9: 106-12.
26. Mokbel K. Current management of ductal carcinoma in situ of the breast. *Int J Clin Oncol* 2003; 8: 18-22.
27. Leonard GO, Swain SM. Ductal carcinoma in situ, complexities and challenges. *J Natl Cancer Inst* 2004; 96: 906-20.
28. Winer EP, Morrow M, Kent Osborne et al. Malignant tumours of the breast. In: DeVita Jr. VT, Hellman S, Rosenberg SA. Eds. *Cancer Principles and Practice of Oncology*. 6th ed. Philadelphia, Lippincott, Williams & Wilkins, 2001:1651-1717.
29. AJCC Cancer Staging Manual: 6th ed. Heidelberg Germany, Springer - Verlag. Reprint 2003:223-40.
30. Fisher B, Anderson S, Redmond CK et al. Reanalysis and results after 12 years of follow-up in a randomized clinical trial comparing total mastectomy with lumpectomy with or without irradiation in the treatment of breast cancer. *N Engl J Med* 1995; 333: 1456-61.
31. van Dongen JA, Voogd AC, Fentiman IS et al. Long term results of a randomized trial comparing breast conservation therapy with mastectomy: European Organisation for Research and Treatment for Cancer 10801 trial. *J Natl Cancer Inst* 2000; 92: 1143-50.
32. Chung MA, Steinhoff MM, Cady B. Clinical axillary recurrence in breast cancer patients after a negative sentinel node biopsy. *Am J Surg* 2002; 184: 310-4.
33. No authors listed. Favourable and unfavourable effects on long term survival of radiotherapy for early breast cancer: an overview of the randomized trials. Early Breast Cancer Trialists' Collaborative Group. *Lancet* 2000; 355: 1757 -70.
34. No authors listed. Polychemotherapy for early breast cancer: an overview of the randomized trials. Early Breast Cancer Trialists' Collaborative Group. *Lancet* 1998; 352: 930-42.
35. Eifel P, Axelson JA, Costa J. National Institute of Health Consensus Development Conference Statement: adjuvant therapy for breast cancer, November 1-3 2000. *J Natl Cancer Inst* 2001; 93: 979-89.
36. Rao SR, Rao RS. Endometrial cancer in a woman on long term tamoxifen therapy. *Bombay Hospital Journal*. 2000; 42: 497-9.
37. Forbes JF. The control of breast cancer: the role of tamoxifen. *Semin Oncol* 1997; 24(Suppl):5-19.
38. Rao SR, Rao RS. Pituitary metastases in carcinoma breast. *J Postgrad Med* 2001; 47: 135-6.
39. Sorosky JI, Scott-Conner CEo Breast disease complicating pregnancy. *Obstet Gynecol Clin North Am* 1998; 25: 353- 63.
40. Patrek JA, Dukoff R, Rogatko A. Prognosis of pregnancy- associated breast cancer. *Cancer* 1991; 67: 869-72.