



Screening for cervical cancer : an overview

Rajendra A Kerkar, Yogesh V Kulkarni

Consultant, Division of Gynaecological Oncology, Tata Memorial Cancer Centre, Mumbai

Key words : cervical cancer, screening methods, Pap smear, liquid based cytology, automated screening technology, HPV-DNA testing, visual inspection of cervix, speculoscopy, cervicography, polar probe, laser induced fluorescence, computer imaging

Introduction

Cancer of the uterine cervix is a leading cause of mortality and morbidity among women worldwide. In developing countries it is the most common gynecological cancer and

one of the leading causes of cancer deaths amongst women. Nearly 400,000 new cases of cervical cancer are diagnosed annually worldwide and 80% of these are diagnosed in the developing countries¹. There are 1.7 million prevalent cases

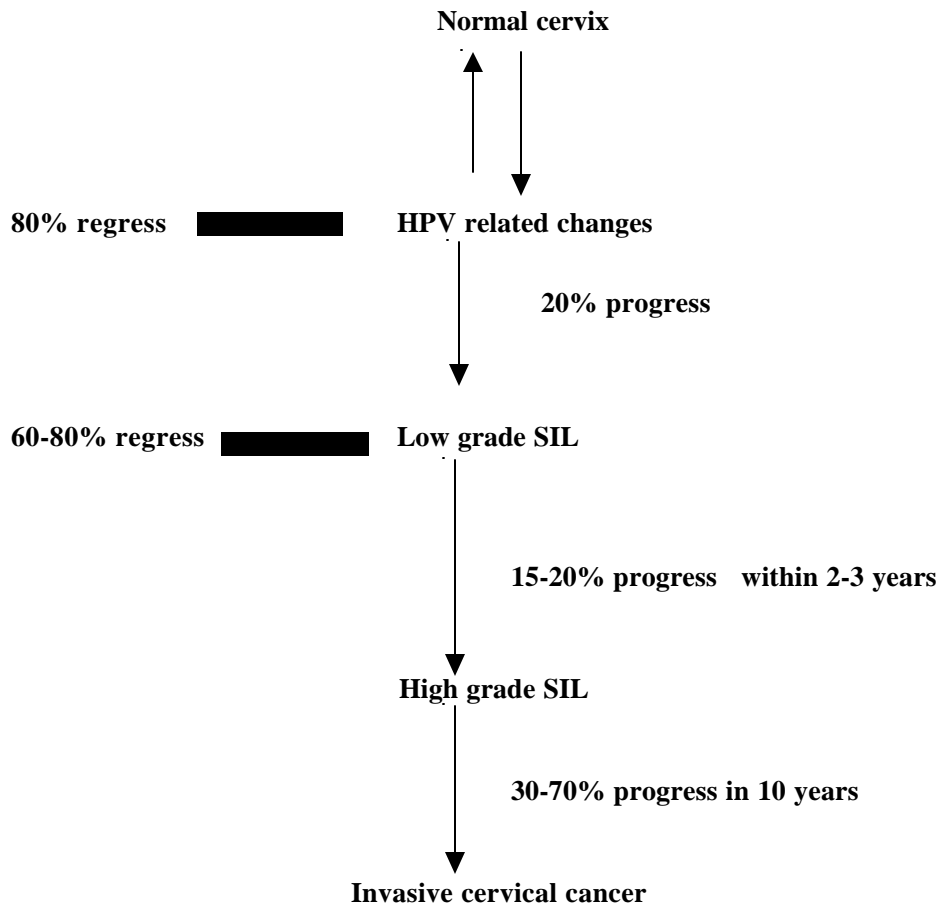


Figure 1. Progression from normal cervix to invasive cancer.

Paper received on 08/12/2005 ; accepted on 06/02/2006

Correspondence :

Dr. Rajendra A. Kerkar
31, Seville, St. Paul's Road,
Bandra West, Mumbai - 400 50.

in the developing world and as many as 5-13 million women have precancerous lesions ². As the female population in the developing countries continues to rise with an increase in life expectancy, the proportion of older women will also necessarily rise. It is expected that the number of cases of cancer cervix will rise further in the years to come.

Natural history of cervical carcinoma

The natural history of cervical cancer represents a stepwise progression from a histologically normal cervix to frank invasive cancer ³ (Figure 1).

Why is screening for cervical cancer effective?

An ideal screening test is one that is minimally invasive, easy to perform, acceptable to the subject, cost-effective and efficacious in diagnosing the disease process in its preinvasive or early invasive state when the disease process is more easily treatable and curable.

In all probability cervical cancer is the only gynecological cancer that satisfies the well recognized WHO criteria for implementation of a screening program –

- ⚡ Existence of well defined premalignant lesions
- ⚡ Long latent period in which premalignant change or occult cancers can be detected and effectively treated thereby altering the natural history of the disease
- ⚡ A clearly defined viral etiology which could be incorporated as a marker in mass screening program
- ⚡ Easy and direct access of the uterine cervix for examination and sampling
- ⚡ Effective treatments available for the premalignant changes.

Screening for cervical carcinoma

Screening programs for cervical cancer have been instituted in developed countries for decades and over a period of time have been shown to be effective in reducing the overall mortality from this disease. Such programs however can only be made to work provided the necessary infrastructure and funds are available ⁴.

Following its introduction by Papanicolau in 1927 ⁵ exfoliative cervicovaginal cytology has been extensively investigated and used as a screening test for cervical cancer. Over the years it has been found that this test has well recognised limitations. A better understanding of the natural history of cervical cancer as also increasing evidence for the putative role of the human papilloma virus (HPV) in its causation has now prompted investigators to find viable alternatives to conventional exfoliative cytology.

A variety of screening tests have therefore been developed in an attempt to overcome the innate limitations of conventional cytology. These are currently under evaluation and it is hoped that they may improve upon the accuracy of conventional screening cytology.

Screening tests for cervical carcinoma

Screening technics for cervical cancer include ⁶ –

- ⚡ Conventional exfoliative cervicovaginal cytology i.e. the cervical (Pap) smear
- ⚡ Fluid sampling technics with automated thin layer preparation (liquid based cytology)
- ⚡ Automated cervical screening technics
- ⚡ Neuromedical systems
- ⚡ HPV testing
- ⚡ Polar probe
- ⚡ Laser induced fluorescence
- ⚡ Visual inspection of cervix after applying Lugol's iodine (VILI) or acetic acid (VIA).
- ⚡ Speculoscopy
- ⚡ Cervicography.

Exfoliative cytology (conventional Pap smear)

Exfoliative cervicovaginal cytology has been regarded as the gold standard for cervical cancer screening programs. Despite the apparent success of the Pap smear in detecting preinvasive cancer, the expected beneficial impact vis-à-vis mortality reduction has not been significant ⁷. The standard technic for Pap smear collection is to sample the portio vaginalis of the cervix and the endocervical canal using a cervical spatula and endocervical brush. The collected sample is smeared on a slide and then fixed immediately with cytology fixative. Most clinicians are concerned with reducing sampling errors by focusing on the technic of smear acquisition and eliminating drying artifacts through rapid fixation.

There are various problems associated with conventional cytology –

- ⚡ Incorrect and inadequate sampling in 5-10% of cases ⁸
- ⚡ Only upto 20% of harvested cells are transferred on the slide leading to a reduction in the sensitivity of the test ⁸
- ⚡ Mean sensitivity of only 55-60% ⁹
- ⚡ Reported false negative rates varying from 25 to 50% ¹⁰
- ⚡ Reported false positive rates varying from 15 to 20 % ¹¹
- ⚡ Interobserver variation in the interpretation of cytological abnormality making reporting subjective and poorly reproducible ¹²
- ⚡ Equivocal smears and mildly irregular Pap results have a

low yield of underlying high grade pathology and represent a significant cost in terms of specialist referral and follow up⁷

- ⚡ Epidemiological data suggest that the current method of Pap smear testing is unlikely to prevent more than 60% of the cases of cervical cancer¹³.

Owing to these problems, several technics have been recently developed in an attempt to automate the various steps of Pap smear preparation and processing in order to try and improve the sensitivity and specificity of conventional cervical cytology.

Fluid sampling technics with automated thin layer preparation

Recently liquid based cytological technologies have been developed and have gained popularity because in preliminary studies the use of such technics was associated with a reduction in the incidence of inadequate cervical smears^{14,15}.

Two such technics that have been extensively tested are ThinPrep (Cytoc Corp, Boxborough, MA) and Autocyte (TriPath Imaging, Burlington, NC). These fluid sampling devices have been approved by the USFDA.

A special sampling device is used for sampling the cervix in the usual manner as in the traditional Pap smear. The sampling device is then directly placed in a vial containing a special preservative with additional hemolytic and mucolytic agents. The general idea is to provide a well preserved sample that is automatically transferred to a slide as a coin sized thin layer. In the laboratory, the cells are collected either by extraction across a special filter (ThinPrep) or by layering onto a density reagent.

Comparisons of the conventional Pap smear with thin layer fluid preparations have shown a marked improvement in the adequacy of the specimen as evidenced by a more even distribution of cells, and reduction in cellular debris and RBCs. This in turn leads to a decrease in the incidence of false positive diagnosis of cytological atypia and an excellent correlation with the detection of squamous abnormalities.

The ThinPrep test was approved for marketing in the USA based upon studies showing an increase in the detection of LSIL or worse, from a rate of 8% by the conventional Pap smear to 9.4% with the ThinPrep¹⁶.

Bernstein et al¹⁷ performed a metaanalysis of 25 prospective studies of the ThinPrep method with a total of 5,33,039 patients. They found that the overall sample adequacy improved with the ThinPrep test (Odds ratio 2.11; 95% CI 2.07-2.15), but the incidence of diagnosis of ASCUS was not reduced (Odds ratio 1.05; 95% CI 0.95-1.16). The overall

sensitivity of the screening test was also found to be increased with ThinPrep.

It is now generally accepted that the improvement in the detection rates with these tests is more marked in centers with a low risk population as compared to those catering to high risk populations (65% improvement as against 6%).

Hartmann et al¹⁸ performed an extensive review of sampling technics and found that most studies of the thin layer technics did not have a proper control group thus hindering the ability to assess the true sensitivity, specificity and predictive value of the technics. They concluded that the current evidence is not adequate enough to recommend that the ThinPrep test is superior to conventional Pap smear testing. They also suggested that the cost-effectiveness of these tests needs to be assessed very carefully as these tests appear to have a lower specificity than conventional Pap smear testing, thus leading to more specialist referrals.

Automated screening technology

The effectiveness of any cervical cancer screening program that relies on cervical cytology is the quality control of the cytological review of Pap smears. This is essential for reducing the false positives and false negatives that invariably result from inter- and intra-observer variation.

Automated screening technics have recently been developed that can not only perform this quality control rescreening but also can be used for primary screening of cervical smears.

The following automated screening technics that rely largely on neural network technology and are based on the computerized imaging and identification of abnormal cervical cells are available –

- ⚡ Autopap300 (TriPath Imaging, Burlington NC)
- ⚡ PAPNET (Neuromedical systems).

Of these, only the Autopap300 is approved by the USFDA for primary and secondary cervical screening while the PAPNET is only approved for secondary screening.

The Autopap300 system utilizes a specialized high speed video microscope, image interpretation software, and specially designed field of view computers to image, analyze and classify abnormal cervical cells. The screened slides are given a score and adequacy statement. Cases scoring a total of 30 or more are then rescreened by a cytotechnologist for further evaluation.

The PAPNET¹⁹ is a semi-automated system, which consists

of two phases, a scanning phase and a review phase for cervical smears. After identification of 128 cells with the highest network score, the cytologists are required to only review those cells.

Wilbur et al ^{20,21} found that considering a 10% review threshold, Autopap300 successfully selected 77% of HSIL slides, which was substantially more than the approximately 10% expected on the basis of a random review. A large multicentric trial has also shown the superiority of the Autopap300 system for the identification of cervical cellular abnormalities at the level of ASCUS or higher.

HPV-DNA Testing

The etiopathological role of HPV in the development of cervical cancer has been proved beyond doubt. HPV 16, 18, 31, 33, 35, 39 45, 51, 52, 56, 59 and 68 are known to be frequently associated with HSIL and invasive cancers of the cervix. Testing for the presence of HPV-DNA in the cervical cells is thus a potentially useful screening method, which could be incorporated in cervical cancer screening programs. There are various technics available for HPV-DNA testing of which Southern Blot hybridization is regarded as a laboratory gold standard. This is however unsuitable for clinical use as it is laborious, tedious and requires fresh tissue. Currently the Hybrid capture II assay (Digene, Silver Spring, MD) is the most useful technic for HPV-DNA testing. This utilizes nonradioactive RNA probes in a modified ELISA procedure to report the presence or absence of 13 strains of high risk HPV-DNA ^{11,22}. The specimen for HPV-DNA testing can be obtained in two ways, either by using a cell suspension from liquid based cytology or by using the endocervical cytobrush.

The Bethesda system and current status of HPV-DNA testing

The Bethesda system for the classification and reporting of abnormal cervical cytology was initially developed in 1988. This was recently revised in 2001 during the Annual Meeting of the American Society for Colposcopy and Cervical Pathology (ASCCP). New guidelines were also developed for the evaluation and management of women with abnormal cervical cytology ¹².

Although the Bethesda system was originally designed to identify all precancerous lesions of the cervix, the focus has now shifted towards facilitating the detection and treatment of high grade cervical intraepithelial lesions (HSIL). This is based on the understanding that most of the low grade lesions (LSIL) especially in young women are associated with self-limiting HPV infections.

Following the development of HPV-DNA testing, this approach has been extensively evaluated for its putative role in the triage and treatment of women with abnormal cervical cytology. This test is currently being used as an adjunct to the conventional Pap smear in the follow-up of patients with ASCUS abnormalities.

Since the majority of such patients are asymptomatic and most of these lowgrade lesions (LSIL) either regress spontaneously or do not progress, the clinical meaning and implication of this test is not fully understood. It has been suggested that in women with ASCUS abnormalities, this test will help to separate those with a true infection needing colposcopy, from those with reactive changes. The test also helps to identify those patients who require aggressive follow-up. Two studies have been critical in identifying and demonstrating role of HPV-DNA testing in such patients.

Manos et al ²³ compared the follow-up with HPV-DNA testing with a routine follow-up with a repeat Pap smear with liquid based cytology. The HPV-DNA test had greater sensitivity for the detection of HSIL and invasive cancer (89%) as compared to a repeat follow-up Pap smear (76%). The number of specialist referrals for colposcopy (40%) were approximately the same in both the groups.

The ASCUS/LSIL Triage Study - The ALTS trial ²⁶ - followed up 3488 women and reported that HPV-DNA testing demonstrated a sensitivity of over 96% for severe CIN lesions, referring 54% women for colposcopy.

In both the studies HPV-DNA testing for women with ASCUS abnormalities was more sensitive and resulted in significantly fewer colposcopy referrals. HPV-DNA testing thus appears to be most useful in determining the appropriate triage of women with ASCUS abnormalities.

It is now accepted that 31-60% of all women with ASCUS will test positive for high risk HPV-DNA ²⁵. According to the newer guidelines these women must be referred for an immediate colposcopy. With a negative predictive value of 98.5% or more, a negative test result proves to be more definitive in reassuring both the patient and the doctor.

The current Bethesda System that is recommended as also the algorithm for the triage and management of women with ASCUS abnormalities is given in Table1 and Figure 2.

Table 1. The Bethesda System.

Epithelial cell abnormality	
ASC-US	Atypical Squamous Cells of Undetermined Significance
ASC-H	Atypical Squamous Cells - cannot exclude HSIL.
LSIL	Low Grade Squamous Intraepithelial Lesion (LSIL) <ul style="list-style-type: none"> ⊄ HPV related changes ⊄ Mild dysplasia ⊄ CIN I
HSIL	High Grade Squamous Intraepithelial Lesion (HSIL) <ul style="list-style-type: none"> ⊄ Moderate and severe dysplasia ⊄ CIN II/III

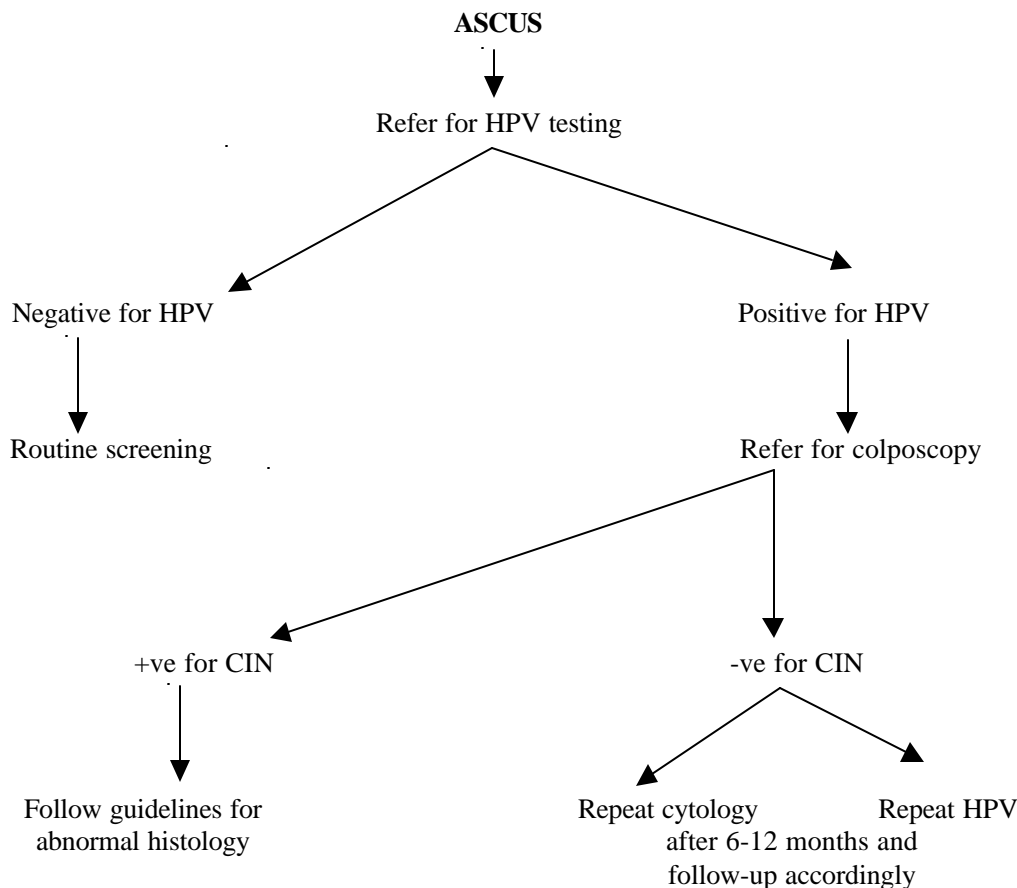


Figure 2. Triage of women with ASCUS abnormality.

Low cost screening strategies for cervical cancer

The screening strategies mentioned above though applicable to the developed world may not be cost effective enough for widespread application in the third world countries. Currently, cervical cytology is widely regarded as the gold standard for cervical cancer screening in all developed countries. It is however not feasible to implement a systematic cytology based screening programme in a country like India. This is mainly due to severe restrictions on the availability of infrastructure, resources, and funding.

There is therefore a need to develop low cost screening strategies for cervical cancer. This will necessarily involve the use of a very simple technics that can be easily taught to and practiced by paramedical personnel in the rural areas. Such technics will need to be cost effective while retaining adequate sensitivity and specificity to perform as practical screening technics.

Visual inspection of the cervix with acetic acid (VIA)

Visual inspection of the cervix both unmagnified and magnified

has been shown to be effective in reducing the morbidity associated with cervical cancer.

The technic is very simple and consists of an examination of the cervix after acetic acid application. After obtaining the clinical history and performing a general examination, the cervix is exposed using a bivalve speculum. A 4% dilute solution of acetic acid is then applied to the cervix and any excess liquid is aspirated from the posterior vaginal fornix.

The cervix is inspected after two minutes. Lesions which stain acetowhite are regarded as positive for VIA. Those with dull white plaques and faint borders are considered low grade VIA while those with sharp borders are considered high grade VIA. The test is regarded as being negative if no acetowhite lesions are detected. Studies have shown that VIA is a reliable, sensitive and cost effective alternative to conventional Pap smear testing, particularly in low resource settings (Table 2).

Table 2. Cervical screening using VIA

	Number	Sensitivity	Specificity	Positive predictive value	Negative predictive value
Shankarnarayan et al ²⁶	3000	90%	92%	17%	97%
Zimbabwe /JHPIEGO ²⁷					
Phase I	8731	NA	NA	25.9%	73.3%
Phase II	2203	76.7%	64.1%	18.6%	96.3%
		44.3%	90.6%	33.3%	93.9%

Speculoscopy

Speculoscopy involves inspection of the cervix following the application of 5% acetic acid with chemiluminiscent light and a low power magnification (4x – 6x).

Published data on speculoscopy appear to suggest that the results with this test are not convincing ^{28,29}. Werteke et al ²⁸ examined the impact of speculoscopy in 5692 women in the primary health care setting and found that the addition of speculoscopy to negative Pap smear resulted in the detection of 11 HSIL, 154 LSIL, 123 reparative changes and 35 normal cervical biopsies. However this does not address the basic issue as to whether the routine addition of speculoscopy to a Pap smear in all cases will improve the outcome by reducing the mortality from cervical cancer. It is however clear that speculoscopy results in a significant increase in the number of women requiring a referral for colposcopy and cervical biopsy, who may well not benefit from this procedure. This implies an increase of 30 colposcopies and cervical biopsies per case diagnosed as HSIL.

Cervicography

Cervicography involves taking photographs of the cervix using a special camera following the application of 5% acetic acid during a routine pelvic examination and Pap smear collection. The photographs are then developed and the slide is projected on a 2x2 meter screen and read by an expert in colposcopy.

The reported sensitivity of cervicography ranges from 44 to 95% ³⁰ and specificity ranges from 58 to 99%. Similar to all newer technologies it is not clear whether the addition of cervicography improves the outcome desired by a screening program for cervical cancer over Pap smear alone. In areas of the world where screening programs are not in place, this technic could possibly have an impact ³⁰.

Investigational strategies for cervical cancer screening

Polar probe

This technology is based upon the fact that the tissue impedance to electrical stimulation differs between normal and abnormal tissues. Investigators have tried to utilize spectral and electrical stimulation of the cervical tissues as an adjunct to conventional Pap smear testing.

The concordance between the findings of a Polar probe assessment and colposcopy/histology ranges from 85% for LGSIL to 90% for HGSIL and to 99% for invasive cancer ³¹. To date, there is a paucity of data to support and recommend this technic outside of a research protocol.

Laser induced fluorescence

Various investigators have shown that low powered laser illumination can induce endogenous tissue fluorescence. This depends upon the chemical and morphological composition of individual tissues. The spectroscopic difference if detectable can be used to differentiate normal and diseased tissues ^{32,33}. This technology is not available for widespread use but may have a role to play in future.

Computer imaging

The diagnosis of precancerous changes is primarily a task of visual discrimination and sorting of graphical information. Recently there has been a lot of focus on the use of computers to assist this process. This is very similar to cervicographic technics except that a computer replaces the colposcopy expert. A prototype of this technic has been described by Craine and Craine ³⁴ with further development by Crisp et al ³⁵. However a lot of research needs to be done to critically evaluate this technology before it can be incorporated into a screening program.

Towards developing a national screening program for cervical cancer

The easy accessibility of the cervix for clinical examination and the existence of clearly defined, easily detectable and easily treatable precursor stages would suggest that cervical cancer can be effectively prevented even in developing countries. What has been lacking in low resource settings has been a realistic match between the resources that are available, cost effective and efficacious methods of detection, and universal and uniform availability of facilities for treatment.

While contemplating the implementation of a screening program that is easily accessible to a large at risk population, it is important to try and identify those factors that might constitute major obstacles to the effective implementation of such a screening program. Having done that, the next step would be the development of a program that is customized to specifically address those issues.

The following are some of the issues that will need to be considered –

- ⚡ Limited public awareness
- ⚡ Limited availability of screening services
- ⚡ Inadequate service provider training
- ⚡ Inadequate cytological services
- ⚡ Inadequate infrastructure, funding, and resources
- ⚡ Difficulty in patient follow-up
- ⚡ Inadequate follow-up services
- ⚡ Inadequate treatment centers
- ⚡ High cost.

Any practical screening program must incorporate public health awareness to address what is truly a public health problem. Local policy makers, clinicians, cytopathologists, women's groups and health administrators must join hands to develop a program that suits available health resources and medical infrastructure.

The following key components will need to be considered while developing a national screening program –

- ⚡ Age at primary screening
- ⚡ Screening frequency
- ⚡ Selection of an appropriate screening test
- ⚡ Approach to the management of an abnormal screening result.

It may be worthwhile to keep the following recommendations of the United States Preventive Services Task Force (USPSTF) in mind while considering the above mentioned issues –

- ⚡ All women who are sexually active should be offered screening
- ⚡ Screening should begin at 21 years or 3 years within starting sexual activity, whichever is earlier
- ⚡ Screening is recommended every 3 years
- ⚡ Screening is not recommended in women more than 65 years, provided they have been regularly screened before and are not at a high risk for cervical cancer
- ⚡ Current evidence is not conclusive to recommend for or against the use of newer technologies
- ⚡ Current evidence is insufficient to recommend for or against the use of routine HPV testing for screening for cervical cancer.

Conclusions

Cytology based screening for cervical cancer is undoubtedly one of the major success stories in the history of medicine and since its inception it has emerged as the gold standard for cervical cancer screening in the developed countries.

In recent years several newer technologies have been developed to try and overcome the acknowledged limitations of conventional Pap smear testing and to improve its sensitivity, specificity and predictive values. It is however very clear that we cannot adopt these technologies as a routine until we provide robust evidence in favor of these techniques by conducting large multiinstitutional studies.

A major challenge for the countries of the third world is to formulate a screening program that is based upon available resources and which is easily available to a large section of society, particularly the rural populations. It is also important to set clear and realistic long term goals. With the active participation of medical personnel, paramedical workers and the local population, a cost effective screening program for cervical cancer needs to be formulated and implemented.

References

1. Parikh DM, Pisani P, Ferlay J et al. Estimates of the world wide incidence of cervical cancer. *Int J Cancer* 1993; 54: 594-606.
2. Bishop A, Sherris TJ. Cervical dysplasia treatment: key issues for developing countries. *Bull Pan Am Health Organ* 1996;30:378-86.
3. Maria ES, Lynne G, Paul DB. Cervical cancer screening in developing countries. *Prim Care Update Ob/Gyn* 2000;7:118-23.
4. Solomon D, Davey D, Kurman R et al. The 2001 Bethesda system:

- Terminology for reporting of cervical cytology. *JAMA* 2002;287:2114-9.
5. Papanicolaou GN. New cancer diagnosis. *Proceedings of the Third Race Betterment Conf.* 1928:528.
 6. Cheryl LR, Clair WM, Kevin R et al. Prevention of cervical cancer. *Critical reviews in Oncology/Haematology* 2000;33:169-85
 7. Cuzick J, Sasieni P, Davies P et al. A systematic review of the role of HPV testing within a cervical cancer screening programme: summary and conclusions. *Br J Cancer* 2000;83:561-5.
 8. Janicek MF, Averette HE. Cervical cancer: Prevention, diagnosis and therapeutics. *CA Cancer J Clin* 2001;51:92-114.
 9. Apgar BS. New tests for cervical cancer screening. *Am Fam Physician* 2001;64:729-31.
 10. Mandelblatt JS, Lawrence WF, Womack SM et al. Benefits and costs of using HPV testing to screen for cervical cancer. *JAMA* 2002;287:2372-81.
 11. Bovicelli A, Bristow RF, Montz FJ. HPV testing: Where are we? *Anticancer Res* 2000;20:4673-80.
 12. Wright TC, Cox JT, Massad LS et al. The 2001 consensus guidelines for the management of women with cervical cytological abnormality. *JAMA* 2002;287:2120-9.
 13. Sasieni PD. HPV screening and cervical cancer prevention. *J Am Med Assoc* 2000;283:538-49.
 14. Howell LD, Bartley RH, Rosenthal DS et al. The autocyte preparation system for gynaecological cytology. *Acta Cytol* 1998;42:171-7
 15. Bishop JW, Bisner SH, Colgan TJ et al. Multicentre masked evaluation autocyte and thinprep thin layer with matched conventional Pap, including biopsy results. *Acta Cytol* 1998;42:189-97.
 16. Lee KR, Ashfaq R, Birasong GG A comparison of conventional Pap smear and fluid based technique for cervical cancer screening. *Obstet Gynecol* 1997;90:278-84.
 17. Bernstein SJ, Sacher-Ramos L, Naubisi B. Liquid - based cytological smear study and conventional Pap smears: A metaanalysis of prospective studies. *Am J Obstet Gynecol* 2001;185:308-17.
 18. Hartmann EK, Nanda K, Hall S et al. Technological advances for cervical cancer screening -Is newer better? *Obstet Gynecol Surv* 2001;56:765-74.
 19. Manso LJ. Neuromedical systems. *Acta Cytol* 1998;81:322-4.
 20. Wilbur DC, Bonfisiolo TA, Rutkewski MA et al. Sensitivity of the Autopap300 system for cervical cytological abnormality and biopsy data confirmation. *Acta Cytol* 1996; 40:127-32.
 21. Wilbur DC, Prey MU, Miller WM et al. The autopap system for primary screening in cervical cytology: comparing the results of a prospective intended-use study with routine manual practice. *Acta Cytol* 1998;42:214-20.
 22. Ouzick J, Sasieni P, Davies P et al. A systematic review of HPV testing within a cervical cancer screening program. *Br J Cancer* 2000;13:561-5.
 23. Manos MM, Kinney WK, Hurley LB et al. Identifying women with cervical neoplasia using HPV-DNA testing for equivocal Pap smear results. *JAMA* 1999;281:1605-10.
 24. Zuna RE, Wang SS, Rosenthal DL et al. ALTS Group Determinants of human papilloma virus-negative, low grade squamous intraepithelial lesions in the atypical squamous cells of undetermined significance /low grade squamous intraepithelial lesions. Triage study (ALTS). *Cancer* 2005;10:253-62.
 25. Sherman ME, Schiffman MJ, Cox JT. ASCUS Lesion Triage Study - Effect of age and HPV viral load on colposcopy triage. *J Natl Cancer Inst* 2002;94:102-07.
 26. Sankaranarayanan R, Wesley R, Thara S et al. Visual inspection of cervix after application of acetic acid for the detection of cervical carcinoma and its precursors. *Cancer* 1998;83:2150-6.
 27. Visual inspection with acetic acid for cervical cancer screening : test qualities in a primary care setting. University of Zimbabwe/ JHPIEGO Project. *Lancet* 1999;353:869-73.
 28. Wertlake P, Francus K, Newkirk G et al. Effectiveness of Pap smear and speculscopy as compared with the Pap smear alone. A community based clinical trial. *Obstet Gynecol* 1997;90:421-27.
 29. Massad L, Lonky N, Mutch D et al. Use of speculscopy in the evaluation of women with atypical Pap smears. Improved cost effectiveness by selective speculscopy. *J Reprod Med* 1993;38:163-9.
 30. Schneider A, Zahm D. New adjunctive methods for cervical cancer screening. *Obstet Gynecol Clin North Am*1996;23:657-73.
 31. Coppelson M, Skalndev V, Darylmp J. An electronic approach to the detection of pre-cancer and cancer of the uterine cervix. A preliminary evaluation of the Polar probe. *Int J Gynecol Cancer*1994;4:79-83.
 32. Schomaker K, Frisoli J, Compton C et al. Ultraviolet laser induced fluorescence of colonic tissue. Basic biology and diagnostic potential. *Lasers Surg Med* 1992;12:63-78.
 33. Lam S, Hung J, Kennedy S et al. Detection of dysplasia and carcinoma in situ by radio fluometry. *Am Rev Resp Dis* 1992;146:1458-61.
 34. Craine BI, Craine ER. Digital imaging colposcopy. Basic technique and its application. *Obstet Gynecol* 1993;82:869-73.
 35. Crisp WE, Craine BL, Craine EA. A computerized digital imaging colposcope - future directions. *Am J Obstet Gynecol* 1990;162:1364-5.