

Varicocelectomy by Subinguinal Cremesteric Disruption and Venous Ligation

Shah Farag A

Nowrosjee Wadia Maternity Hospital, Mumbai - 400 012

OBJECTIVE - To analyze treatment outcome after outpatient subinguinal cremesteric disruption and venous ligation in infertile male with abnormal semen parameters. **METHODS** - A prospective study was carried out at a tertiary referral center for treatment of infertility. Three hundred infertile men with varicocele and abnormal semen parameters were included. Outpatient subinguinal cremesteric disruption with venous ligation was performed on all them. The main outcome measures were improvement in sperm counts and pregnancy rate. **RESULTS** - Two hundred and forty two (80.7%) of the 300 men achieved pregnancy leading to live births. The total number of motile sperms per ejaculate increased from $0.08 \pm 0.02 \times 10^6$ before the surgery to $7.5 \pm 2.5 \times 10^6$ after it. **CONCLUSION** - Subinguinal outpatient cremesteric disruption and venous ligation is a physiological, economical, and safe option for varicocele repair in men with abnormal sperm parameters. High rate of unassisted pregnancy is achievable with minimum morbidity.

Key words: varicocele, male infertility, ambulatory varicocele

Introduction

A varicocele is observed in 35 to 40% of men with primary infertility and in up to 80% of men with secondary infertility. Varicocele is the most common treatable cause of infertility and its repair has been demonstrated to improve semen quality and fertility potential in men with abnormal semen parameters'. Various out patient techniques have been described for repair of varicoceles, including microsurgery", emobilization", and laparoscopy". These techniques have generated renewed interest in the treatment of varicocele because they limit morbidity, decrease recurrence rate and seem more acceptable to the patients.

However, some investigators were unable to demonstrate improvement among their own patients following varicocelectomy/:". There are many unanswered questions about varicocele. Numerous theories have been suggested for the development of varicocele'PF, especially the absence of valves in the spermatic vein and the so called nut cracker phenomenon.

While most of these theories suggest a cause above the deep inguinal ring, none explains the clinical evidence of absence of venous tortuosity above the deep inguinal ring. We believe that it is not a retrograde flow in the spermatic vein but a venous stasis induced by a tight cremesteric compartment around the spermatic cord

which leads to dilatation and tortuosity of the spermatic veins. Based on above concept we suggest a subinguinal ambulatory approach for varicocele repair with emphasis on cremesteric disruption.

Materials and Methods

Patientselection

Between January 1995 and October 2000 a total of 798 patients were referred to the out patient clinic dedicated for treatment of men with infertility in our tertiary care unit. A detailed history was obtained and a complete physical examination performed. A minimum duration of infertility, defined as failure to establish a pregnancy with appropriately timed and unprotected intercourse of 12 months duration was required for study group entry. Physical examination was performed by a single investigator. Spermatic cords were observed and palpated while the patient stood upright and performed Valsalvas maneuver. Testicular size was documented.

Scrotal ultra sonography with color doppler imaging was used to confirm the physical findings and detect subclinical varicoceles. Based on the findings, varicoceles were graded as -

Large	(Visible and Palpable)
Moderate	(Palpable)
Small	(Detected by Doppler reflux with greater than 2.7 mm venous diameter)

The semen parameter for all patients were below threshold levels viz., less than 20 million per ml or less than 50% motility or less than 40% normal

Paper received on 16/6/03 ; accepted on 21/10/03

Correspondence :

Dr. Parag A. Shah

11, Yogesh Sadan, Higwala Lane, Ghatkopar-East, Mumbai - 400 077, India.

Tel : 022-5137834

morphological forms. Of the 798 infertile men 336 (42%) were detected to have varicocele. A total of 408 varicocelectomies were performed on 300 patients.

Surgical Technique

All procedures were performed as outpatient surgeries. Premedication consisted of 0.6mg of oral atropine. Skin was infiltrated with 3 to 5 ml of a mixture of 1% lidocaine and 0.5% bupivacaine (1:1) over the external inguinal ring and into the spermatic cord. A small 2 cm incision was made over the external ring (Fig 1). The subcutaneous tissue was separated by sharp and blunt dissection and small band retractors exposed the spermatic cord. One to 2 ml of local anesthetic was injected under the cremasteric fascia of the exposed spermatic cord. The anesthetised exposed segment of the spermatic cord was elevated out of the incision by gentle traction and sharp dissection. The band retractor was placed below the spermatic cord for support. Dilated posterior cremasteric veins if present were ligated and transected. The cremasteric fascia and the muscle encircling the exposed spermatic cord were completely dissected (Fig 2). The vas deference and the testicular artery were observed and retained out of the field. Only the grossly dilated spermatic veins (more than 3 mm in diameter) were isolated, ligated and transected

No attempt was made to ligate all the vessels and spermatic veins. No sclerosing agent was used to obliterate collateral and perforating branches. Operative microscope was not used to assist the surgery. The spermatic cord was replaced in its bed and the incision closed with an absorbable suture.

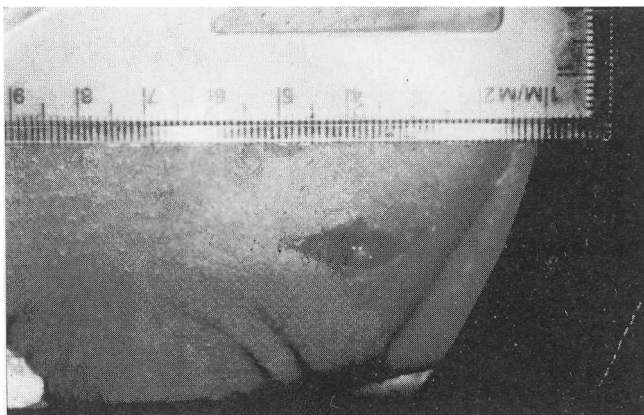


Fig 1 : A 2 cm long incision is taken 2 cm above and lateral to the public tubercle.

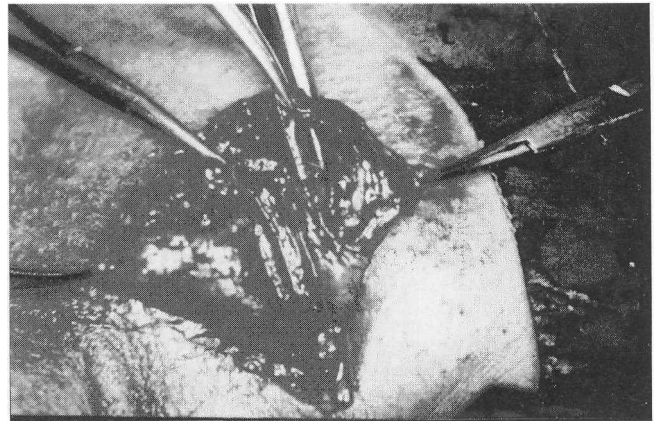


Fig 2 : The spermatic cord is hooked out of the incision. Cremasteric fascia and muscle is dissected and a sleeve excised. Dilated veins are ligated.

Results

A total of 408 procedures were performed on 300 patients. There were 292 cases of primary infertility and 8 cases of secondary infertility. Mean age of the patients was 28.7 ± 6.3 years (range of 21 to 46 years). The varicocele was left unilateral in 122 cases (40%), bilateral in 108 cases (36%) and right unilateral in 70 cases (24%). The mean duration of infertility was 26.3 ± 16.5 months (range 12 to 120 months). The varicocele was large in 106 cases (36%), moderate in 154 (51%) and small in 40 (13%).

Semen specimens were collected and evaluated according to world health organization criteria". Mean total number of motile sperms per ejaculate was $0.08 \pm 0.02 \times 10^6$ (range 0.06×10^6 to 0.2×10^6); 213 cases (71%) had less than 50% motility.

All operations were performed on an out patient basis and the operation time averaged 15 minutes (range 10 to 25 minutes) per side. The most common problem was transient local discomfort in 21 patients (7%). There was only one case of hydrocele. No recurrences were palpable over a two year follow up. There were no cases of testicular atrophy.

Over a period of one year the mean total number of motile sperms per ejaculate increased to $7.5 \pm 2.5 \times 10^6$ to 10×10^6 . All the cases had sperm motility greater than 50%. The one year pregnancy rate was 64% (192 patients) which increased to 80.2% (242 patients) over a two year period.

Discussion

Treatment options for men with suboptimal semen parameters who desire to contribute to a pregnancy with their own biological materials include **lesl** with ejaculated sperm or testicular sperm extraction. The

couple thus relies on assisted reproductive techniques which are not only expensive but unnatural and disturbing to their routine activity. The widespread availability of ICSI has led some gynecologists and reproductive endocrinologists to 'bypass' both the evaluation and treatment of the male while proceeding straight to assisted reproduction. This is unfortunate because many cases of male infertility are caused by correctable conditions such as varicocele.

A 'cost per delivery' analysis revealed that varicocelectomy is three times more cost effective than ICSI in USA¹³. The European experience estimated it to be seven times more cost effective". In India, varicocelectomy may be 10 to 20 times more cost effective than ICSI. This study shows that infertile men with varicocele can expand their reproductive option after surgery". Semen parameters were improved for most men and 242 couples (80%) achieved an unassisted pregnancy.

Numerous approaches have been reported for varicocele repair. We have chosen to perform our surgeries on outpatient basis under local anesthesia. This approach has less risk than that for general anesthesia required for laparoscopy and retro peritoneal varicocelectomy. We believe that the tight cremasteric compartment encircling the spermatic cord causes venous stasis and subsequent tortuosity of the spermatic veins in a localised area up to the deep ring. We thus emphasise complete disruption of the cremasteric fascia and muscle to achieve the desired results. Only the abnormally dilated veins are transected with no emphasis on complete venous occlusion. Since this does not require major dissection the chances of damage to the testicular artery and subsequent testicular atrophy (nil in our series) or damage to the lymphatics and subsequent hydrocele (0.3%) in our series) are minimised. Others have reported an incidence of up to 7.2% hydrocele formation after varicocelectomy by the inguinal and retroperitoneal approach.

The most common complaint following modified subinguinal varicocelectomy was wound discomfort. This was easily managed by conservative measures like non-steroidal anti-inflammatory drugs. The patients usually returned to work after 24 hours of surgery.

The morbidity of this procedure was less than the inguinal or retroperitoneal surgery, which required dissection of the muscle layers or the inguinal canal. Laparoscopic varicocelectomy may have lowered the morbidity rate but this approach requires intra-peritoneal exploration and has the potential for significant complications such as bowel perforation and bleeding. Our operating time was approximately 15

minutes per side, which was significantly less than that needed by some laparoscopists Kbaier et al" needed as long as 177 minutes for laparoscopic varicocelectomy.

High ligation and retroperitoneal approaches are subject to high recurrence rate ranging from 1 to 8%¹. Since meticulous venous dissection and ligation is not advocated in our approach it may be concluded that there would be a high incidence of recurrence. However, no palpable recurrence was demonstrated over a two year follow up of our patients. Analysing the reports of different investigators it was observed that those undertaking the subinguinal approach for varicocele repair" had better pregnancy rates (30% to 60%), compared to those reported after other approaches. We infer that the inguinal or subinguinal varicocelectomies resulted in advent, unintentional, partial or complete disruption of the cremasteric fibers leading to better results.

References

1. Magdar I, Weissenberg R, Lunenfeld B et al. Controlled trial of high spermatic vein ligation for varicocele in infertile men. *Fertil Steril* 1995; 63: 120-4.
2. Goldstein M, Gilbert BR, Dicker AP et al : Microsurgical Varicocelectomy with delivery of the testis: an artery and lymphatic sparing technique. *JUrol* 1992; 148: 1808-12.
3. Marmar JL, Kim Y: Subinguinal microsurgical varicocelectomy: A technical critique and statistical analysis of semen and pregnancy data. *JUrol* 1994; 152: 1127-1132-34.
4. White R. I j-. Kaufman S L, Barth K H et al. Occlusion of varicoceles with detachable balloons. *Radiology*, 1981; 139: 327-31 .
5. Aaberg R A Vancaillie T G, Schuessler W W Laparoscopic varicocele ligation : a new technique. *Fertil Steril* 1991; 56: 776-8.
6. Kbaier I, Binous M, Attyaoui F. Laparoscopic spermatic vessel ligation in the treatment of varicocele: Report of 129 procedures. *Ann Urol*. 2002; 36: 329-33 .
7. Nilsson S, Edvinsson B. Improvement of semen and pregnancy rate after ligation and division of the internal spermatic vein: fact or fiction? *Brit J Urol* 1979; 51:591-4.
8. Vermuelen A, Vanderweghe M. Improved fertility after varicocele correction: fact or fiction? *Fertil Steril* 1984; 42: 249-52.

9. Evers J, Collins J. Assessment of efficacy of varicocele repair for male subfertility: A systematic review. *Lancet*, 2003 : 361 (9372) : 1838-9.
10. Mail W P. Th. M., Oei H Y, Arndt J W et al. Hemodynamics of the varicocele. Part 1. Correlation among the clinical, phlebographic and scintigraphic findings. *JUral* 1986; 135: 483-9.
11. Verstoppen G R, and Steeno O P. Varicocele and the pathogenesis of the associated subfertility. A review of the various theories and results of surgery. *Andrologia* 1977; 9: 293-7.
12. Dada R, Gupta N, Kucheria K. AZF microdeletion associated with idiopathic and nonidiopathic cases with cryptorchidism and varicocele. *Asian JAndrol* 2003; 4:259-63.
13. Schlegel PN: Is assisted reproduction the optimal treatment for varicocele associated male infertility? *A cost-effective analysis. Ural* 1997; 49: 83-5.
14. Comhaire F: Economic strategies in modern male subfertility treatment. *Hum-Reprod* 10 (Suppl. 1): 1995; 103-6.
15. Cayan S, Erdemir F, Ozbey I. Can varicocelectomy significantly change the way couple use assisted reproductive technologies? *JUral* 2002; 167, 1749-52.