

# Malignant Melanoma of the Female Urethra

Nupur Hooja', Mridul Cehlot', Premlata Mital', Arpita [indal', Abha Sethi"

Departments of 'Obstetrics and Gynecology and of Pathology, S.M.S. Medical College, [aipur and Zenana Hospital", [aipur.

Key words: malignant melanoma, urethra

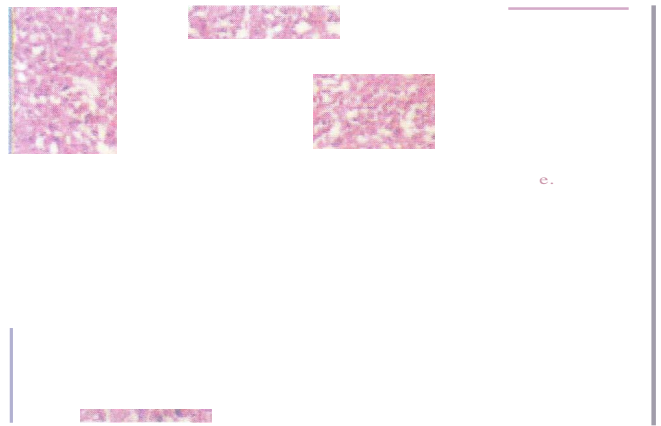
## Introduction

Carcinoma of the female urethra accounts for less than 1% of female cancers and 60% of these are squamous cell carcinoma. Malignant melanoma is rare comprising less than 2% of all urethral carcinomas. We report one such case.

## Case Report

A 45 year old, Hindu woman was seen on 5th June, 2000 with complaints of a gradually increasing swelling near the urinary orifice with difficulty in passing urine. On examination, a soft, fleshy, 5 cm wide growth was seen near the external urethral meatus. Initially, it appeared to arise from the anterior wall of the vagina but examination under anesthesia revealed it to be arising from the posterior part of the external urethral meatus. Vaginal examination findings were normal. A biopsy of the growth was taken. Histopathological study reported malignant melanoma. Six cycles of chemotherapy with mitomycin, 5-FU and vincristine was started on 5th November 2000. It was spread over 7 months due to development of low blood counts during therapy. She was also given external radiotherapy of 50 Gy to the pelvis. At the end of chemoradiation, the patient continued to have increased frequency of micturition, incontinence of urine and foul discharge. The mass at the external urethral meatus, reduced in size to 1 cm. It was soft, fleshy, well localized at the external urinary urethra, superficial and free from underlying tissue. No lymph nodes were palpable. Chest x-ray was normal. Cystoscopy showed no bladder involvement. CT scan did not show any tumor lesion elsewhere. She was operated on 12th September, 2001 and circumferential local excision of the distal urethra and adjacent vaginal wall was done. Catheter was removed on the 14th post-operative day. Urinary continence was maintained. Histopathology revealed malignant melanoma (Photograph 1 and 2). Cut margins were free from the

tumor. She was discharged against medical advice on 28th September, 2001. Further chemotherapy was advised, which she refused and she was not seen again.



Photograph 1. Malignant melanoma. Magnification 100x.

Photograph 2. Malignant melanoma. Magnification 400x.

## Discussion

Malignant melanoma of the female urethra is very rare. The patient's ages range between 32 and 80 years'. The presenting symptoms include dysuria, frequency, terminal hematuria and the presence of a mass. The tumor may present as a submucosal mass in the anterior wall of the vagina". It may be difficult on initial physical examination to differentiate malignant tumors of the urethra from those of the vulva or vagina. Survival

Paper received on 1/9/02 ; accepted on 21/8/03

Correspondence :

Dr. Nupur Hooja

A-29, Lal Bahadur Nagar, Opp. Hotel Clarks Amer, Malviya Nagar, [aipur - 302 017.

Tel. 0141 550851 Email:hoojas@datainfosys.net

depends on the stage, location and size of the neoplasm at the time of diagnosis. Histologic characteristics do not affect the prognosis significantly and all histologic types are treated in a similar manner". Extensive surgery alone or high dose irradiation alone produce high morbidity and low tumor control rate. Studies recommend combined modality approach of preoperative irradiation and combination chemotherapy with mitomycin -C, SF, uracil or M-VAC followed by surgery". Therapy should be based on the stage of the lesion at presentation and not on location or cell type<sup>3</sup>. Because urethral carcinoma is so rare, no single institution has a series with enough patients to prospectively examine different treatment protocols". Since the tumor was small, well localized, superficial, and free from underlying tissue, circumferential local excision of the distal urethra and anterior vaginal wall was done by us. Bracken et al" in a series of 64 patients have shown that 5 year survival rates vary between 18% and 45% depending on the stage of the disease and that they were higher at 60% for tumors <2 cm at initial presentation than 13% for tumors >5 cm . They emphasized the need for early diagnosis. Websiter" reported 5 year survival rate between 13% and 40% for

different stages and 26% as a whole. Kim et al reported a 5 year survival of 12% (6 patients) in a series of 48 cases.

## References

1. Kim CJ, Pak K, Hamaguchi A et al. Primary malignant melanoma of the female urethra. *Cancer* 1993; 71:448-51.
2. Walsh PC, Retik AB, Vaughan A. Jr. et al. *Campbell's Urology 7<sup>th</sup> edition Vol 3. Philadelphia. W. B. Saunders Company*, 1998: 3407-9.
3. Poore RE, McCullough DL. Urethral Carcinoma., In Gillenwater JY, Grayhalk JT, Howards SS et al, eds. *Adult And Pediatric Urology 3<sup>rd</sup> ed. Missouri: Mosby 1996; p. 1837-50.*
4. Bracken R B, Johnson DE, Miller LS et al. Primary carcinoma of the female urethra. *JUro*11976; 116: 188-92.
5. Webster GD. The urethra. In: Paulsondf, ed. *Genitourinary Surgery. New York, Church Livingstone 1984; 399-405.*