

# Malignant Melanoma of Vagina with Pathological Fracture of Femur Neck

Jaya Joseph

Department of Obstetrics and Gynecology, St. John's Medical College Hospital, Bangalore - 560 034.

Key words: malignant melanoma of vagina, fracture femur

A case of malignant melanoma of vagina with positive right internal iliac lymphadenopathy presenting with fracture neck of the femur after radical radiotherapy and chemotherapy is reported.

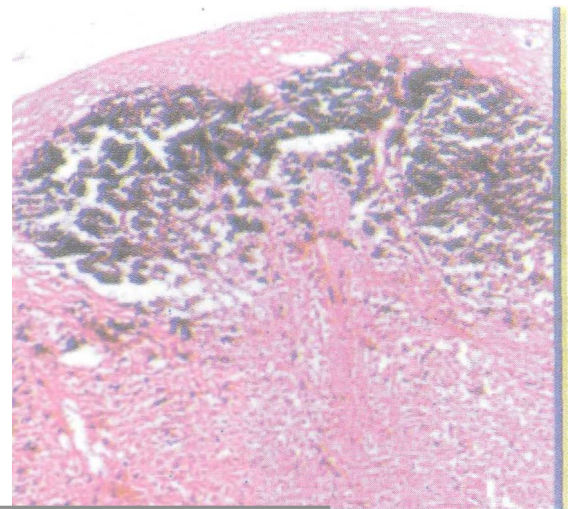
## Case Report

Mrs G, a 72 year old postmenopausal multipara came on 20th April, 2002 with history of increased frequency of micturition and foul smelling vaginal discharge for two months. She was a known hypertensive, on treatment with atenelol. On examination she was clinically stable, with no peripheral lymphadenopathy, no organomegaly and no abdominally palpable mass. Speculum examination revealed cauliflower growth involving whole of vagina. It was friable, had necrosed areas and bled on touch. Cervix was flush with the growth and healthy. Vaginal examination revealed a retroverted normal size uterus. Adnexas were free. On rectal examination, the rectal mucosa was free of growth. Pelvic sonography showed an atrophic uterus which measured 7.2 x 2.9 x 2 cm and had endometrial thickness of 12 mm. CT scan revealed a bulky vagina, 4.7 x 4 cm, with fluid in the uterus and right internal iliac lymphadenopathy.

Histopathology of punch biopsy from the growth revealed stratified squamous epithelium which was hyperplastic with some koilocytic changes. The ulcerative areas of the neoplasm were composed of sheets of round to oval to stellate cells, exhibiting moderate degree of nuclear pleomorphism and ill defined cytoplasmic borders were seen with few scattered large cells with hyperchromatic nuclei and well defined cytoplasmic borders. Many cells contained brown pigment. The neoplasm was rich in vascularity. The Masson Fontana stain showed positivity of the pigment in the cytoplasm.

The neoplasm was reported to be spindle cell malignant melanoma of vagina.

The patient was given radiotherapy (RT). A total of 4500 cGy of RT was given in 25 fractions, 5 fractions per week. She was referred to an oncology center and received chemotherapy with cyclophosphamide and dacarbazine followed by inj. Intron 3 million IU weekly for 3 months and inj Immuvac 0.1 ml weekly for 3 months. She presented with spontaneous fracture of the neck of the femur after 3 months of the completion of therapy. She was treated with hemiarthroplasty with Austin Moor prosthesis. She did not have any gynecological complaints. Speculum examination revealed the growth involving whole of vagina more on the anterior aspect. Vaginal examination was inconclusive due to fibrosis. Whole body scan revealed multiple foci of increased skeletal tracer uptake over 03 and 06 vertebrae, in left 10<sup>th</sup> and right 6<sup>th</sup> rib, multiple foci on the right 2<sup>nd</sup> and left 2<sup>nd</sup>, 4<sup>th</sup> and 8<sup>th</sup> ribs, and a focus in the midshaft of left clavicle suggestive of metastasis. However, histopathological study of the resected head of femur did not show any evidence of malignancy. Post-operative period was uneventful.



Photograph 1. The Masson Fontana Stain highlighting the black melanin pigment present in the spindle shaped melanotic tumour thus obscuring their cytology.

Paper received on 04/06/03 ; accepted on 04/12/03

Correspondence:

Dr. Jaya Joseph

Department of Obstetrics and Gynecology,

St. John's Medical College Hospital, Bangalore - 560 034.

E-mail : sjmch@vsnl.com

## Discussion

Primary melanoma of vagina is a rare disease. It constitutes less than 3% of vaginal cancers' and only 0.3% of all melanomas<sup>2,3</sup>. Extensive literature search failed to reveal any case of fracture or bone metastasis in vaginal melanoma. The incidence of skeletal metastasis in malignant melanoma is reported to be 0.82%<sup>4</sup>. Patten et al<sup>5</sup> state that of the metastasis in malignant melanoma 17% are bony metastasis (sites not mentioned) with 87.5% of them being osteolytic, 46.6% causing cortical erosion and destruction, and 22.5% causing fractures. The 5 years survival in patients with vaginal melanoma is notoriously poor and is estimated to be between 13% by Weinstock<sup>6</sup> and 19% by Ragnorsson - Olding et al<sup>2</sup>. Controversy still surrounds the optimal treatment for vaginal melanoma. No therapeutic approach like wide excision or radiotherapy alone or the two in combination with adjuvant therapy with interferon alfa 2b has a clear benefit in treating this aggressive disease", The prognosis continues to be poor with any mode of treatment.

## References

1. Chung AF, Casey MJ, Flannery JT et al. Malignant melanoma of vagina - report of 19 cases. *Obstet Gynecol*1980; 55: 720-7.
2. Ragnorsson-Olding B, Johansson H, Rutqvist LE et al. Malignant melanoma of the vulva and vagina. *Cancer* 1993; 71: 1893-7.
3. Weinstock MA. Malignant melanoma of the vulva and vagina in the United States: Pattern of incidence and population based estimates of survival. *Am J Obstet Gynecol*1994; 171: 1225-30.
4. Potepan P, Spagnoli I, Oanesini GM et al. The radiodiagnosis of bone metastasis from melanoma. *Radial Med (Torino)* 1994; 87:741-6.
5. Patten RM, Shuman WP, Teegy S. Metastasis from malignant melanoma to axial sketeton : a CT study of frequency and appearance. *Am J Roentgenol* 1990; 155: 109-12.
6. Buchanan OJ, John Schlaerth J, Kurosaki T. Primary vaginal melanoma. Thirteen year disease free survival after wide local excision and review of recent literature. *Am J Obstet Gynaecol*1998; 178: 1177-82.